

Comparison of Efficacy and Safety of Postoperative Topical Low Concentration Mitomycin-C Versus Higher Concentration Per Operative on- Flap Mitomycin-C in Trabeculectomy in Pakistani Population

KHALID MAHMOOD, MUHAMMAD HANNAN JAMIL*, MUHAMMAD TARIQ*, AMJAD SALEEM SAHI*, ZAHEERUD DIN AQIL QAZI*

ABSTRACT

Objective: To compare the efficacy and safety of post-operative, low concentration topical Mitomycin-C (MMC) versus conventional Intra-operative higher concentration Mitomycin-C in trabeculectomy in Pakistani population

Study design: Quasi-Experimental

Place and duration: Layton Rahmatullah Benevolent Trust Hospital (LRBT), Lahore May 15, 2008 to Nov 20, 2009.

Methods: Seventy eyes of 70 patients were divided randomly into groups 1 & 2 of 35 eyes each. Group 1 received topical (over conjunctival surface) 3 minute application of Mitomycin-C (0.1 ml of 0.05mg/ml) for three consecutive days post-operative, using a 5x5mm micro sponge. Group 2 received per-operative episcleral 3 minute application of Mitomycin-C (0.1 ml of 0.2mg/ml) using 5x5mm micro sponge. The patients were followed for 1 year to see if the intraocular pressure (IOP) stays equal to or below 21 mmHg without medication. Any complication that occurred during this period was made note of.

Results: No statistical difference in surgical success rate was found between Group 1 and 2. After 1 year, Group 1 had a 97%, whereas Group 2 had 85.7% success rates respectively. Serious complications were low among both groups. In Group 1, one eye developed corneal epithelial defects. In Group 2, one eye developed endophthalmitis and another hypotony related maculopathy.

Conclusion: Topical Mitomycin-C applied post-operatively for 3 consecutive days in lower concentrations is safe and at least as efficacious as Intra-operative higher concentration MMC in lowering IOP.

Key words: Glaucoma, Intra-ocular pressure, Trabeculectomy, Antimetabolites, Mitomycin-C

INTRODUCTION

Glaucoma is the third commonest cause of blindness in Pakistan¹. Widespread poverty and illiteracy in this region mainly contributes towards very late presentation in majority of patients². Lack of effective district based eye care services is another hurdle in the course of early glaucoma management. Fairly advanced nature of the disease at presentation and non-affordability of the poor patients mostly leaves no choice but to opt for surgical intervention.

In our settings it is a common observation that vast majority of patients visiting the glaucoma clinic eventually end up in filtering surgery somewhere in their course of disease. Trabeculectomy with and without antimetabolites is the most common filtering surgery performed in our region³ with variable

rate (even in non-complicated cases) is expected to be high in pigmented races as ours. Antimetabolites, if on one hand have proven to enhance the surgical success rate, are certainly not without some serious side-effects⁶ including corneal epithelial toxicity, anterior chamber shallowing, hypotony related maculopathy as well as bleb leaks and scleral thinning.

The basis of performing this study was to put to test a novel method of applying Mitomycin-C in a 4-fold lesser than usual concentration but on the conjunctival bleb rather than conventional subtenon/episcleral surface. This was applied post operatively for three consecutive days instead of once during the surgery (conventional). In this way we believed that we can still obtain the beneficial effect of Mitomycin-C without the unwanted serious complications owing to using it in a very low concentration.

Department of Ophthalmology, Avicenna Medical College/Hospital, Lahore, *LRBT Eye Hospital, Lahore
Correspondence to Dr. Khalid Mahmood, Associate Professor
Email: eyesaver66@yahoo.com Cell 0322 4222700

MATERIAL AND METHODS

Seventy eyes of 70 patients with indications for augmented trabeculectomy with antimetabolite were enrolled from the out-patient glaucoma clinic at LRBT Eye Hospital Lahore. The study was carried out in the period of May 15, 2008 to November 20, 2009. The patients were divided using non probability convenient sampling into two groups 1 & 2 of 35 eyes each. After taking informed consent, a complete socio-demographic data was recorded. Detailed pre-operative examination included best-corrected visual acuity, anterior and posterior segment with special emphasis on the optic nerve status and measurement of intraocular pressure with the help of Goldmann applanation tonometer. Gonioscopy was performed in every patient to see the anterior chamber angle status and to help identify/classify the glaucoma.

Trabeculectomy was performed in a routine fashion as devised by Watson and Cairns. In all eyes a fornix based conjunctival flap was raised. Surgery was done under local anaesthesia using 2-3 ml of retrobulbar injection of xylocaine only.

Group 1 received post-operative topical application of MMC (0.1 ml of 0.05mg/ml) using a soaked 5x5mm cellulose micro sponge placed over the conjunctival bleb for 3 minutes (on-flap application). Few drops of ocular visco-elastic device (OVD) were placed on cornea beforehand to protect inadvertent damage and to avoid epithelial toxicity. After application the eye was copiously irrigated with ringer lactate solution to wash away MMC. This procedure was repeated at about the same hour for three consecutive days after surgery using freshly prepared MMC.

Group 2 received single per-operative application of MMC (0.1 ml of 0.2mg/ml) using a soaked 5x5mm cellulose micro sponge placed between episclera and overlying tenon's capsule in the region of scleral flap for 3 minutes.

All the patients were seen on the next post operative day and then followed at 1 week, 1 month, 3 months, 6 months and finally at 1 year. Intra-ocular pressure (IOP) was taken using Goldmann applanation tonometer and any complication was made note of at each visit. Surgical success was considered if the IOP could be brought down to 21mmHg or below after surgery, without antiglaucoma medication. The complications that were looked for included hypotony ($IOP \leq 6mmHg$) associated maculopathy, scleral thinning, perforated bleb, corneal epithelial defects and blebitis/ endophthalmitis.

RESULTS

Figure 1 shows age groups distribution between Group 1 and 2. Majority of the patients in both groups were between 40 to 60 years of age. There were 18 males and 14 females in Group 1 and 16 males and 15 females in Group 2. Considerable majority of the glaucomas included in the study happened to be secondary and/or complicated. Figure 2 highlights various types of glaucoma and their distribution between the two groups.

IOP of every patient was recorded at each visit. One eye from group 1 and two from group 2 had to be started antiglaucoma therapy during the study, therefore their IOP values were excluded in calculating the mean post-op IOP at year end, which was 13.03 mmHg for Group 1 and 13.86 mmHg for Group 2. The Mean Pre-op IOPs were 38.74 and 39.37 for Group 1 and Group 2 respectively.

Surgery was considered successful when IOP could be brought down to 21 mmHg or below (without medication). Table 1 compares the success ratio for group 1 and 2 at various follow up visits. Group 1 had a 97% (34 out of 35), whereas Group 2 had 85.7% (30 out of 35) success rate respectively after 1 year. Considering the *p*-value this was established that there is no statistically significant difference between the surgical success rates in either group after 1 year.

Overall complication rate for both groups remained very low. Only 1 patient in group 1 developed punctate corneal epithelial erosion during early postoperative period. This was probably due to inadvertent MMC corneal contact. The patient recovered within few weeks with extensive use of lubricants and was symptom free after 1 month.

In both groups next-day post-operative shallow anterior chamber (AC) with low IOP was fairly common with 8 eyes from Group 1 and 11 eyes from Group 2. In such cases the routine was to use topical Atropine drops and then applying tobramycin-dexamethasone ointment before pressure patching the eye for 24-48 hours. The 2nd and 3rd day postoperative topical applications of MMC were skipped for these eyes from Group 1. In response to this maneuver, by one week well maintained anterior-chamber was seen in all but one eye from Group 2 which progressed to develop hypotony related maculopathy. Another case from Group 2 developed Endophthalmitis after 7 weeks of surgery. The conjunctival bleb was not thin or perforated. He responded well to single injection of Intravitreal vancomycin + Cefuroxime + dexamethasone while his vitreous culture report was inconclusive.

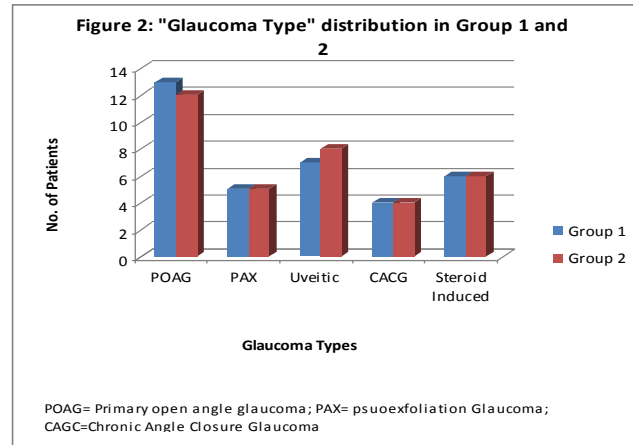
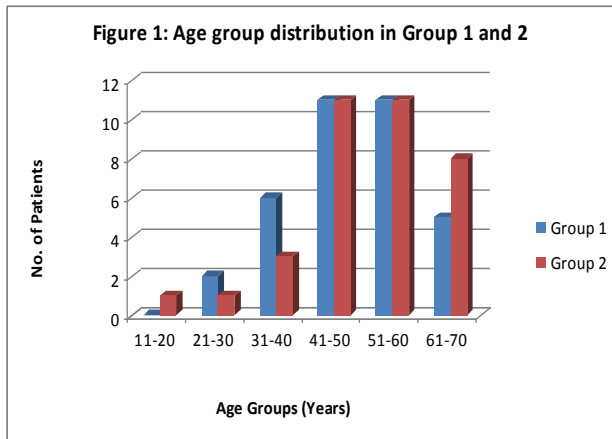


Table 1: Success ratio comparison between Group 1 and Group 2

Follow up	Group 1		Group 2		Significance (p) Fisher's exact test
	Successful	Failed	Successful	Failed	
1 Day	35	0	35	0	
1 Month	35	0	34	1	1.00
3 Month	35	0	32	3	0.23
6 Month	34	1	30	5	0.19
1 Year	34	1	30	5	0.19

Successful= IOP ≤ 21 mmHg (without medication)

Failed= IOP > 21 mmHg or ≤ 21 with medication

DISCUSSION

Since the introduction of mitomycin-C to glaucoma surgery⁷, several clinical studies have shown the efficacy of MMC in improving the outcome of trabeculectomy⁸. This has been demonstrated for cases of both uncomplicated^{9,10} as well as complicated¹¹ glaucomas. Mostly the concentrations of MMC used are 0.5 mg/ml¹², although other authors used 0.2mg/ml¹³ or 0.1 mg/ml¹⁴ as well. The rationale for these different concentration seems to be clinical experience.

Although MMC has been used on a regular basis for more than 14 years, very few variations are known when it is used other than MMC-soaked sponge placed on the sclera. In 2002 Mietz H. from USA described that if MMC, in significantly low concentration is applied topically over the conjunctival bleb postoperatively, the beneficial effect of MMC can still be obtained with significantly low complication rates¹⁵. This took us to find out the outcomes in pigmented races as ours where Trabeculectomy (*with MMC*) failure rate is considered higher than the white races.

Our study implies that both modes of application of MMC are equally efficacious in terms of lowering an IOP to equal or below 21 mmHg without medication in Pakistani population. For this novel application method of topical MMC, the patient has to be admitted for at least 3 days and meticulous effort is mandatory while applying topical MMC onto the bleb to avoid inadvertent sponge-corneal contact. In addition fresh preparations of MMC on all three

postoperative applications increased the total cost of procedure. In comparison the Intra-operative application requires less hospital admission duration and is less costly owing to single MMC preparation requirement. The only rationale for using topical application instead of the intra-operative technique is the formers equaling efficacy in terms of IOP control even when using MMC in 4 times lesser concentration then the later. Complications like scleral thinning, bleb leak^{16,17} etc. usually occur years later after the use of antimetabolites. With the usage of weaker concentrations of MMC one can assume fewer chances of serious side-effects.

Kitazawa et al investigated the two MMC concentrations, 0.2 mg/ml and 0.02 mg /ml, for primary procedures in patients with primary open angle glaucoma¹⁸. Although the incidence of complications was similar between the two groups, the control of IOP was better in the first. However because each group consisted of 11 eyes and the patients did not have secondary glaucoma, it is difficult to determine whether the low concentration of MMC had any affect at all. If we analyze Figure 2, many cases that were included in our study had an increased risk for failure, so we can speculate that the results without MMC would have been worse. In addition, the failure rate compared with the intra-operative episcleral 0.2 mg/ml MMC is not significantly different. Therefore we conclude that MMC even in weaker concentration when applied topically does have an equivalent effect.

This study might be limited due to a small number of patients. Nevertheless, fortunately we were able to get sufficient follow-up information from all patients and the cases were included on consecutive basis, therefore it is believed that the implications can be relied upon. In our study 1 year follow-up period was considered sufficient to draw 'surgical success' conclusions based on the assumption that episcleral fibrosis starts soon after the surgery and if the bleb is functional after 1 year it is highly probably to remain functional.

An important complication that we encountered during the study and that has been repeatedly commented on in the context of MMC surgery is 'hypotony'. Explanations to why this hypotony develops still remain controversial. Several studies suggest toxic effects of MMC on the ciliary body epithelium. This explanation was substantiated by Gandolfi et al¹⁹ who injected MMC sub conjunctively in human eyes with end stage glaucoma without performing a trabeculectomy. The author found reduced IOP values afterwards. In morphologic studies damage to ciliary body epithelium has been demonstrated to occur both in human and rabbit eyes²⁰, and histopathologic abnormalities of excised MMC filtering blebs have been demonstrated. Whether these changes really cause excessive leakage of aqueous through the conjunctival bleb is unclear.

CONCLUSIONS

In summary the results of the study are highly encouraging for postoperative application of low concentration MMC. The surgical success rate is as at least as good as the conventional on-flap application while being safe owing to a lower concentration of MMC used. The method can be safely adopted in pigmented races where use of MMC is indicated.

REFERENCES

- Dineen B, Bourne R, Jadoon Z, Shah S, Khan MD. Causes of blindness and visual impairment in Pakistan. The Pakistan national blindness and visual impairment survey. *Br J Ophthalmol*: 2007; 91(8):1005
- Fraser S, Bunce C, Wormald R, Brunner E. Deprivation and late presentation of glaucoma: case-control study. *Br J Ophthalmol*: 2001; 322(7287):639
- Qureshi MB, Khan MD, Shah MN. Glaucoma Admissions and Surgery in Public Sector Tertiary Care Hospitals in Pakistan: Results of a National Study. *Ophthalmic Epidemiol*: 2006; 13(2):115-9
- Baig MSA, Ahmed J, Ali MA. Trabeculectomy with Mitomycin-C. *Pak J Surg*: 2008; 24(1):49-52
- Jalal T, Mohammad S. Three years retrospective study of patients undergone Trabeculectomy in Lady Reading Hospital Peshawar. *J Postgrad Med Inst*: 2004; 18(3):487-94
- Laube T, Ritters B. Clinical experiences and results of application of mitomycin C in trabeculectomy. *Klin Monbl Augenheilkd*: 2003; 220(9):618-24
- Chen CW, Huang HT, Bair JS, Lee CC. Trabeculectomy with simultaneous topical application of mitomycinC in refractory glaucoma. *J Ocul Pharmacol*: 1990; 6:175-82
- Bindlish R, Condon GP, Schlosser JD, D'Antonio J, Lauer KB, Lehrer R. Efficacy and safety of mitomycin-C in primary trabeculectomy: five-year follow-up. *Ophthalmology*: 2002; 109(7):1336-41
- Reibaldi A, Uva MG, Longo A. Nine-year follow-up of trabeculectomy with or without low-dosage mitomycin-c in primary open-angle glaucoma. *Br J Ophthalmol*: 2008; 92(12):1666-70
- Jongsareejit B, Tomidokoro A, Mimura T, Tomita G, Shirato S, Araie M. Efficacy and complications after trabeculectomy with mitomycin C in normal-tension glaucoma. *Jpn J Ophthalmol*: 2005; 49(3):223-7
- Mietz H, Krieglstein GK. Mitomycin C for trabeculectomy in complicated glaucoma: preliminary results after 6 months. *Ger J Ophthalmol*: 1994; 3(3):164-7
- Kupin TH, Juzych MS, Shin DH, et al. Adjunctive mitomycin-C in primary trabeculectomy in phakic eyes. *Am J Ophthalmol*: 1995; 119:30-9
- Mietz H, Krieglstein GK. Three-year follow-up of trabeculectomies performed with different concentrations of mitomycin-C. *Ophthalmic Surg Lasers*: 1998; 29(8):628-34
- Alwitary A, Abedin A, Patel V, Moodie J,. Primary low-risk trabeculectomy augmented with low-dose mitomycin-C. *Eur J Ophthalmol*: 2009; 19(6):971-6
- Mietz H, Jacobi PC, Krieglstein GK. Intraoperative episcleral versus postoperative topical application of mitomycin-C for trabeculectomies. *Ophthalmology*: 2002; 109:1343-9
- Palanca-Capistrano AM, Hall J, Cantor LB, Morgan L, Hoop J, WuDunn D. Long-term outcomes of intraoperative 5-fluorouracil versus intraoperative mitomycin C in primary trabeculectomy surgery. *Ophthalmology*: 2009; 116(2):185-90
- Anand N, Arora S, Clowes M. Mitomycin C augmented glaucoma surgery: evolution of filtering bleb avascularity, transconjunctival oozing, and leaks. *Br J Ophthalmol*: 2006; 90(2):175-80
- Kitazawa Y, Kawase K, Matsushita H, Minobe M. Trabeculectomy with mitomycin. A comparative study with fluorouracil. *Arch Ophthalmol*: 1991; 109:1693-98
- Gandolfi SA, Vecchi M, Braccio L. Decrease of intraocular pressure after subconjunctival injection of mitomycin in human glaucoma. *Arch Ophthalmol*: 1995; 113(5):582-5.
- Hong SJ, Wu KY, Wang HZ, Lai YH. Toxic effects of mitomycin-C on cultured ciliary process cells and trabecular meshwork cells. *J Ocul Pharmacol Ther*: 2001; 17(4):331-4

